

eContouring for Thoracic Malignancies

Katelyn Atkins, MD PhD

Interim Chair, Clinical Director, Associate Professor

Cedars-Sinai Medical Center, Los Angeles, California

Disclosures

- Revolution Medicines (consulting, honoraria)
- Varian Medical Systems (grant, to institution)

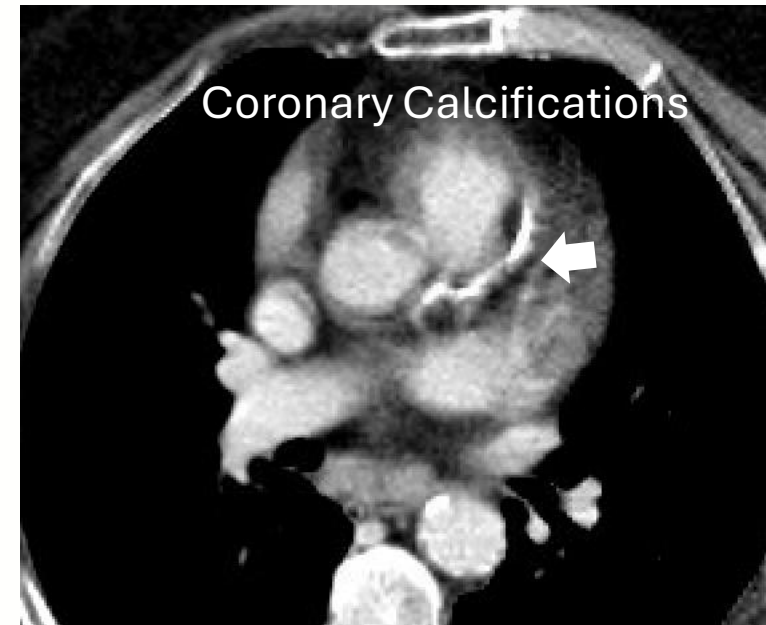
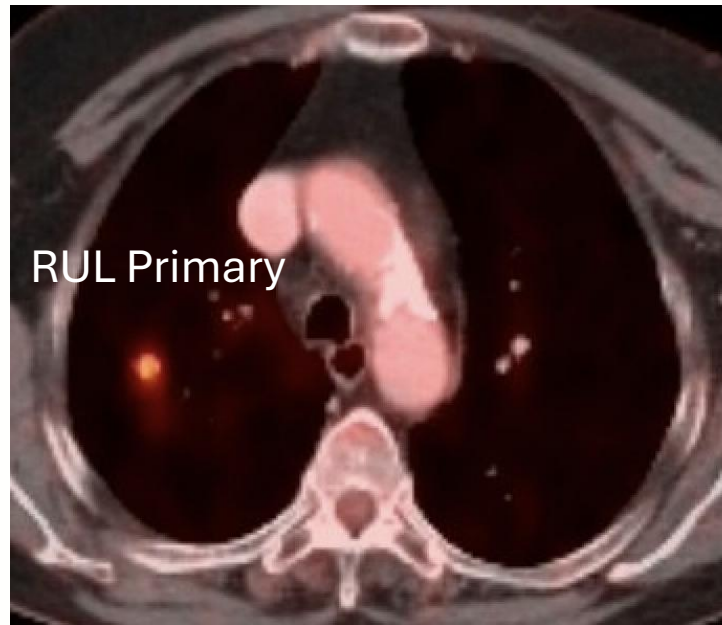
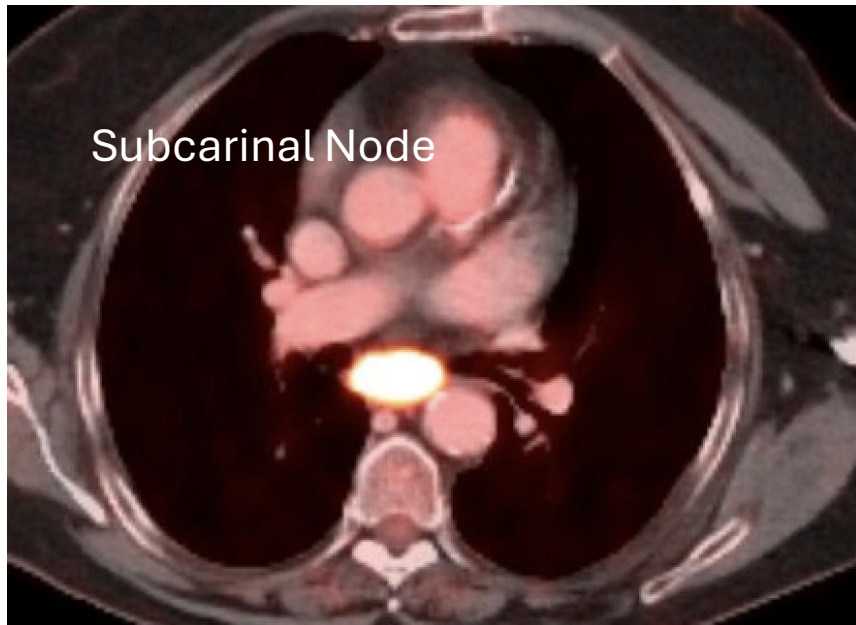
Case Presentation and eContouring Exercise

Case 1 – Locally Advanced NSCLC

- 73F with history of hypertension, hyperlipidemia, 30 PY tobacco use, T2DM, CAD, with new diagnosis of stage IIIA (cT1cN2M0) RUL NSCLC adenocarcinoma (KRAS G12Cmt, PD-L1 1%), initially planned for neoadjuvant chemo-immunotherapy
- On pre-operative workup developed unstable angina, requiring left heart cath and LAD stent placement, no longer surgical candidate
- After multi-disciplinary discussion, definitive chemoradiation to 60 Gray with outback durvalumab was recommended

Case 1 – Locally Advanced NSCLC

- PET/CT shows FDG-avid subcarinal LN and small RUL primary.
- The patient has known cardiac disease; the presence of coronary calcium is noted on your planning CT.



Case 1: Questions?

- How should respiratory motion be accounted for during CT simulation for locally advanced lung cancer?
- How should a 4D-CT be utilized for iGTV and/or CTV/ITV delineation?
- What cardiac sub-substructures should be contoured?
- What dose constraints may be used for these sub-structures and with what planning priorities (ie target coverage vs OARs)?

Case 1: eContouring Exercise

- Practice Contouring Targets:
 - Lymph node in station 7: iGTV (on Ave, 0%, and 50%), CTV (on Ave)
- Practice Contouring Left Coronary Arteries:
 - Left main (LMCA), Left anterior descending (LAD) – Can combine LMCA with LAD into single LAD structure (on Ave)
 - Left circumflex coronary (LCX) (on Ave)

Case 1: eContouring Exercise

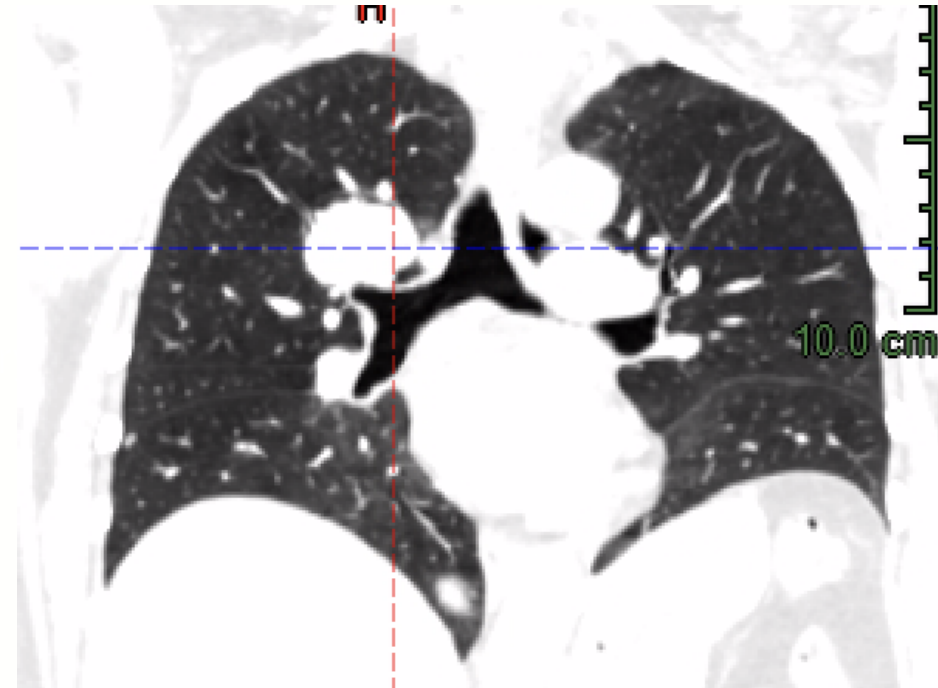
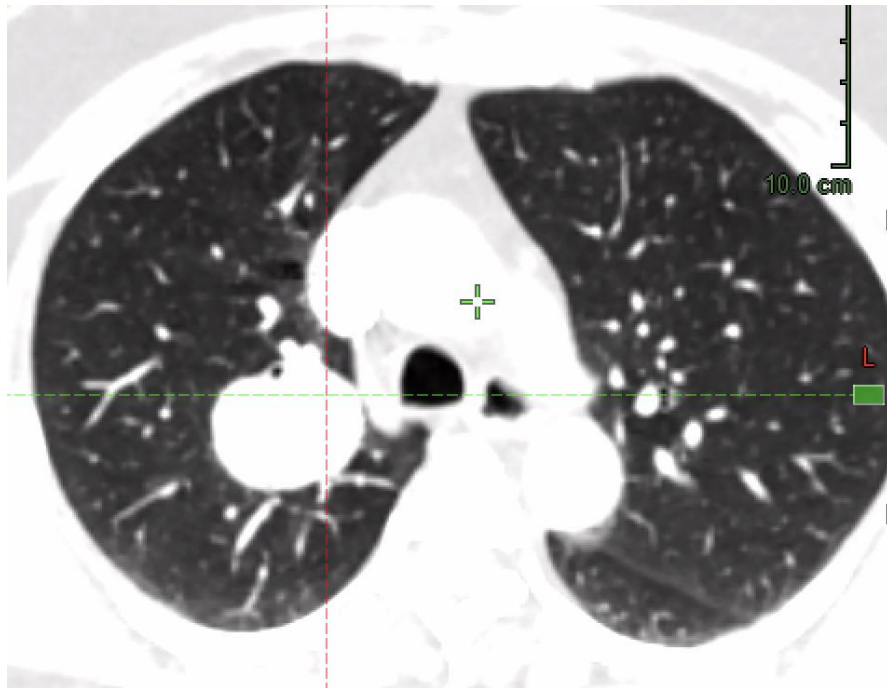
- Recommended Contouring Plan: Slice-Specific Contours
 - Ave Scan, 0%, 50%:
 - Slice 57:
 - iGTVn_station7, CTV_station7 (Ave, 0%, 50%)
 - LAD (Ave only)
 - Slice 62:
 - iGTVn_station7, CTV_station7 (Ave, 0%, 50%)
 - LAD, LCx (Ave only)

Case 2 – Ultracentral Oligo-metastasis

- 61F with no significant past medical history, renal cell carcinoma diagnosed in 2018 (resected, pT1aN0), with oligo-metastatic recurrence to pancreatic tail in 2022 (s/p resection), with several small pulmonary nodules, then oligo-progression in 3.6 cm LUL metastasis
- After multi-disciplinary discussion, local oligo-met directed treatment was recommended (RT/SBRT)

Case 2 – Ultracentral Oligo-metastasis

- CT shows increased growth in 3.6 x 2.8 cm RUL mass with additional (stable) small (<1cm) pulmonary nodules



Case 2: Questions?

- What critical organs-at-risk should be contoured?
- What dose constraints should be applied to these structures?
- What planning priorities should be applied (ie target coverage vs OARs)?

Case 2: eContouring Exercise

- Recommended Contouring Plan: Slice-Specific Contours
 - DIBH #1
 - Slice 83:
 - Recommended: iGTV, bronchus (proximal bronchial tree [PBT]),
 - Optional: A_pulmonary, V_venacava_S, A_aorta
 - Slice 81:
 - Recommended: iGTV, bronchus (proximal bronchial tree [PBT])
 - Optional: V_venacava_S